



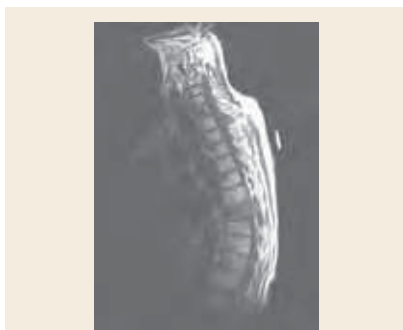
# Nurse, My Back Hurts: Understanding Malignant Spinal Cord Compression

Joyce A. Marrs, MS, APRN-BC, AOCNP

Malignant spinal cord compression (SCC) is an oncologic emergency. SCC can be caused by direct extension of a tumor into the spinal cord or metastasis to the vertebral column, resulting in increased pressure on the spine (Huff, 2005; Prasad & Schiff, 2005; Purdue, 2004). Approximately 10%–15% of patients with cancer may develop SCC. See Figure 1 for a radiology image of SCC.

SCC is seen most often in metastatic cancer of the (Flounders & Ott, 2003; Held-Warmkessel, 2005; Huff, 2005; Prasad & Schiff, 2005)

- Breast
- Lung
- Prostate.



*Note.* Magnetic resonance image of left paraspinal mass eroding adjacent osseous structures with compression on the left side of the spinal cord at the T3 vertebral body level

**Figure 1. Spinal Cord Compression**

*Note.* Image courtesy of Douglas Ditzel, DO, at Miami Valley Hospital in Dayton, OH. Used with permission.

SCC also may be seen with

- Non-Hodgkin lymphoma
  - Multiple myeloma
  - Renal carcinoma
  - Colorectal cancer
  - Pancreatic cancer
  - Sarcoma
  - Cancer of unknown primary origin.
- Nonmalignant causes of SCC include (Flounders & Ott, 2003)
- Herniated disc
  - Fractures of the vertebrae as a result of osteoporosis

- Abscess in the spinal column
- Herpes zoster.

## Symptoms

Symptoms of SCC vary depending on the area of spinal cord involvement and the extent of compression. See Table 1 for distribution of spinal levels affected by SCC. The amount of impairment and loss of function with which patients present for treatment are predictive for the expected outcome. Loss of function rarely

**Table 1. Area of Occurrence With Malignant Spinal Cord Compression**

AREA OF SPINE AFFECTED	CASES (%)	CANCERS ASSOCIATED WITH SITE
Thoracic	70	Lung, prostate, or breast
Lumbar	20	Gastrointestinal or prostate
Cervical	10	Breast
Multiple levels affected	30	—

*Note.* Based on information from Flounders & Ott, 2003; Huff, 2005; Prasad & Schiff, 2005; Purdue, 2004.

Joyce A. Marrs, MS, APRN-BC, AOCNP, is a nurse practitioner at Hematology and Oncology of Dayton in Ohio.

Digital Object Identifier: 10.1188/06.CJON.114-116

Downloaded on 01-04-2025. Single-user license only. Copyright 2025 by the Oncology Nursing Society. For permission to post online, reprint, adapt, or reuse, please email pubpermissions@ons.org. ONS reserves all rights.