



# Changes in Breast Radiotherapy: Prone Positioning and Hypofractionation

Maria Fenton-Kerimian, APN-BC, OCN®, Olivier Maisonet, FNP-BC, OCN®, and Silvia C. Formenti, MD

Breast cancer management has drastically changed since the 1990s. Many patients with breast cancer now can opt to conserve their breast through a lumpectomy and radiation (breast conservation therapy), rather than a full mastectomy. Advances in the techniques of delivery and length of breast radiotherapy have been rapidly evolving. This article attempts to summarize some of those changes for nurses caring for patients with breast cancer during radiation therapy.

Maria Fenton-Kerimian, APN-BC, OCN®, is an administrative nurse practitioner coordinator, Olivier Maisonet, FNP-BC, OCN®, is a nurse practitioner, and Silvia C. Formenti, MD, is the chairman of radiation oncology, all in the Department of Radiation Oncology and Department of Nursing at the NYU Langone Medical Center in New York, NY. The authors take full responsibility for the content of the article. No financial relationships relevant to the content of this article have been disclosed by the authors or editorial staff. Fenton-Kerimian can be reached at [maria.fenton-kerimian@med.nyu.edu](mailto:maria.fenton-kerimian@med.nyu.edu), with copy to editor at [CJONEditor@ons.org](mailto:CJONEditor@ons.org).

Digital Object Identifier: 10.1188/13.CJON.550-553

The American Cancer Society (2013) estimated 232,340 new cases of invasive breast cancer will be diagnosed among women in the United States in 2013. Many patients diagnosed with breast cancer will require radiation therapy as an integral part of their cancer management. Breast conservation therapy (BCT) involves a lumpectomy (partial mastectomy) followed by breast irradiation. BCT allows patients to keep the integrity of their own breasts without compromising local control of the breast cancer.

## Breast Conservation Therapy

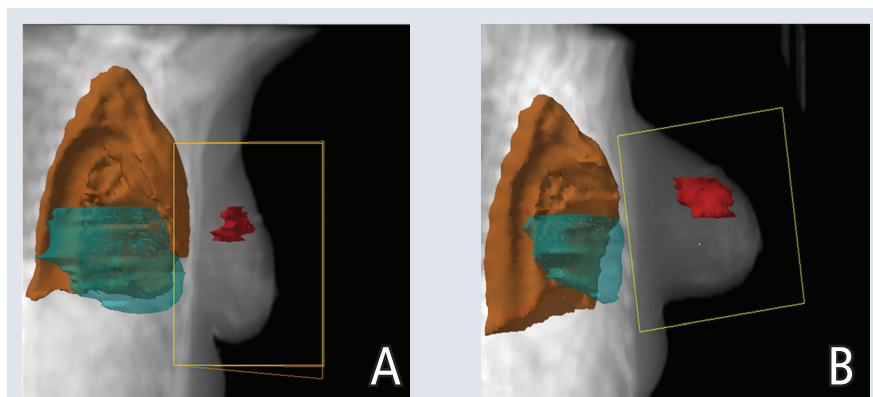
Fisher et al. (2002) reported evidence gathered during a 25-year period that showed BCT can be the appropriate therapy for women with breast cancer who have negative surgical margins. Women in this pivotal trial were treated with lumpectomy and radiotherapy over five weeks without increased recurrence rates, proving that lumpectomy followed by irradiation continues to be appropriate therapy for women with breast cancer. The historical trial confirmed the

merit of breast conservation radiotherapy. Historically, breast radiation following lumpectomy always was delivered in the supine position, which has the patient lying face up; the prone position, however, involves the patient lying face down, sometimes with the hands behind the head or neck.

Darby, McGale, Taylor, and Peto (2005) reported that U.S. cancer radiotherapy regimens from the 1970s–1980s appreciably increased mortality 10–20 years following treatment from heart disease for left-sided breast cancer and lung cancer in the ipsilateral lung. During the study time frame, 1973–2001, women were treated with radiation in the supine position. A subsequent study update in 2013 demonstrated a proportional increase in the rate of coronary events per Gy of radiation to the heart, even for women without a baseline cardiac risk at the time of radiation (Darby et al., 2013). In the 25 years since the advent of BCT, radiation therapy delivery methods have vastly improved, lowering the amount of irradiation to the heart and lungs during treatment (Formenti et al., 2007).

## Radiotherapy Positioning

When patients are treated with breast radiotherapy in the traditional supine



Note. Yellow box shows the beam's eye view of the treatment field. Images show the left-sided breast cancer (A) supine then (B) prone, demonstrating the sparing of the heart (blue) and the lung (brown).

### FIGURE 1. Beam's Eye View of the Treatment Field

Note. Images courtesy of the Department of Radiation Oncology at the NYU Langone Clinical Cancer Center. Used with permission.