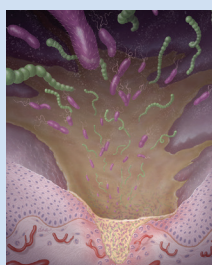


# Review of Therapies for the Treatment of Oral Chronic Graft-Versus-Host Disease

Margaret Harvey Granitto, MSN, RN, CRNP, Jane M. Fall-Dickson, PhD, RN, AOCN®, Colleen K. Norton, PhD, RN, CCRN, and Colleen Sanders, MS, RN, FNP



© DNA Illustrations/Science Source

Oral chronic graft-versus-host disease is a frequent complication of allogeneic hematopoietic stem cell transplantation, contributing to patient morbidity and mortality. Although an optimal treatment is not available, several systemic and topical or local therapies have shown efficacy in treating the disease. New therapies are being tested through clinical trials. This article examines the efficacy and safety of reported treatment modalities studied from 2006–2012. Nurses will encounter patients with oral chronic graft-versus-host disease suffering from pain, discomfort, and a decreased quality of life. Knowledge of new therapies found to be effective in managing these symptoms is imperative. Nurses play a key role in the assessment and management of this complex oral disease.

Margaret Harvey Granitto, MSN, RN, CRNP, is an instructor, Jane M. Fall-Dickson, PhD, RN, AOCN®, is an associate professor and assistant chair, research, Colleen K. Norton, PhD, RN, CCRN, is an associate professor and director of the BSN Program, and Colleen Sanders, MS, RN, FNP, is an instructor, all in the School of Nursing and Health Studies in the Department of Nursing at Georgetown University in Washington, DC. The authors take full responsibility for the content of the article. The authors did not receive honoraria for this work. The content of this article has been reviewed by independent peer reviewers to ensure that it is balanced, objective, and free from commercial bias. No financial relationships relevant to the content of this article have been disclosed by the authors, planners, independent peer reviewers, or editorial staff. Granitto can be reached at [mhg24@georgetown.edu](mailto:mhg24@georgetown.edu), with copy to editor at [CJONeditor@ons.org](mailto:CJONeditor@ons.org). (Submitted March 2013. Revision submitted May 2013. Accepted for publication June 1, 2013.)

Key words: oral chronic graft-versus-host disease; clinical trials; allogeneic hematopoietic stem cell transplantation

Digital Object Identifier: 10.1188/14.CJON.76-81

**G**raft-versus-host disease (GVHD) is a serious complication experienced by patients following allogeneic hematopoietic stem cell transplantation (HSCT) that contributes to morbidity and mortality (Imanguli, Pavletic, Guadagnini, Brahim, & Atkinson, 2006). GVHD develops when grafted immunocompetent T cells (transplanted stem cells) recognize and reject foreign antigens on the host (recipient) cells, leading to a T cell-mediated inflammatory reaction (Morton & Fontaine, 2011). Acute GVHD usually manifests within 100 days following HSCT, and chronic GVHD (cGVHD) generally develops more than 100 days following HSCT. cGVHD occurs in 30%–60% of patients surviving more than 100 days postallogeneic HSCT, and may present as late as one year after HSCT (Lee & Flowers, 2008; Morton & Fontaine, 2011). It typically occurs in patients who have had acute GVHD. Reduced relapse rates have been seen in allografted patients who developed GVHD when compared with patients who did not develop the disease. The graft-versus-tumor effect reduces relapse rates because host antigen-presenting cells during the first months after HSCT cause efficient donor T cell immunization against host hematopoietic cells (Baron et al., 2005).

The most frequent sites involved in cGVHD at time of diagnosis are the skin, mouth, liver, and eyes (Lee & Flowers, 2008). Standard treatment of cGVHD consists of systemic immunosuppressive therapy, usually with steroids, for periods of two to seven years. That therapy, in addition to the chronic immunodeficiency and organ damage caused by the cGVHD, contributes to increased morbidity and mortality (Lee & Flowers, 2008). Although optimal treatment is not yet available for cGVHD manifesting in the oral cavity, patients with oral cGVHD need to receive the best available therapy to decrease disease severity and related symptoms, as well as to minimize the associated negative effects on their health-related quality of life (HRQOL) and nutritional status (Fall-Dickson et al., 2010).

## Clinical Presentation

Oral involvement often is the first manifestation of the disease (Imanguli et al., 2006). Almost 80% of patients with cGVHD have oral clinical signs, including atrophy, edema, erythema, lichenoid changes, ulcerations, and late fibrosis, which often lead to poor jaw range of motion (Imanguli et al., 2006). Lichenoid changes are similar in clinical presentation to oral lichen planus and have a