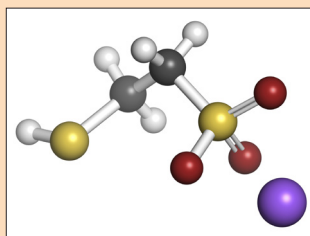


# Preventive Measures for Cyclophosphamide-Related Hemorrhagic Cystitis in Blood and Bone Marrow Transplantation: An Italian Multicenter Retrospective Study

Silvia Gonella, MSc, BNS, RN, Tania di Pasquale, BNS, RN, and Alvisa Palese, MSc



© Molekuul/Stock/Thinkstock

**Background:** Hemorrhagic cystitis (HC) is a troublesome and potentially life-threatening complication of bone marrow transplantation (BMT). HC can appear within a few hours after chemotherapy or after weeks or months. Early-onset HC (EOHC) is usually associated with the conditioning regimen.

**Objectives:** The main aim of this study was to describe the incidence of EOHC in patients undergoing BMT regimens with high-dose cyclophosphamide (CY) and the effects of the main preventive measures adopted in Italian nursing practice.

**Methods:** The authors retrospectively analyzed the clinical records of 158 Italian patients who underwent BMT from 2006–2008.

**Findings:** Thirty-one patients (20%) developed EOHC. One hundred and forty-seven patients (93%) given high-dose CY were treated with hyperhydration combined with 2-mercaptoethane sulphonate and diuresis alkalinization, and only 51 (32%) patients were preventively catheterized and received continuous bladder irrigation (CBI). By univariate analysis, prophylactic urethral catheterization and CBI did not decrease EOHC incidence, questioning if these measures should be routinely recommended. Previous studies showed increased discomfort and urinary tract infection in catheterized patients; therefore, nurses may fulfill an important role in balancing the benefits and harms of preventive catheterization and CBI in patients who received BMT conditioning with high-dose CY.

Silvia Gonella, MSc, BNS, RN, is a nurse in the Department of Public Health and Community Medicine at the University of Verona; and Tania di Pasquale, BNS, RN, is an RN and Alvisa Palese, MSc, is an associate professor, both in the School of Nursing at Udine University, all in Italy. The authors take full responsibility for the content of the article. The authors did not receive honoraria for this work. The content of this article has been reviewed by independent peer reviewers to ensure that it is balanced, objective, and free from commercial bias. No financial relationships relevant to the content of this article have been disclosed by the authors, planners, independent peer reviewers, or editorial staff. Palese can be reached at [alvisa.palese@uniud.it](mailto:alvisa.palese@uniud.it), with copy to editor at [CJONEditor@ons.org](mailto:CJONEditor@ons.org). (Submitted March 2014. Revision submitted May 2014. Accepted for publication May 30, 2014.)

Key words: transplantation; cystitis; hemorrhage; prevention measures; advanced nursing care

Digital Object Identifier: 10.1188/15.CJON.E8-E14

**H**emorrhagic cystitis (HC) is a troublesome and potentially life-threatening complication of bone marrow transplantation (BMT) (Xu et al., 2007). This condition significantly affects patients' quality of life, increases the length of hospitalization, and can lead to death if the condition is intractable (Xu et al., 2007). The Karolinska Center for Allogeneic Stem Cell Transplantation in Sweden has defined HC as painful hematuria with negative urine culture for bacteria or fungus and without any other explanation, such as general bleeding diathesis, urinary tract catheterization for reasons other than HC, urinary calculi,

and bladder neoplasm (Hassan et al., 2007). Similarly, Lee et al. (2003) defined HC as the presence of microscopic or macroscopic hematuria in the absence of other clinical conditions, such as menstruation, general bleeding diathesis, disseminated intravascular coagulation, multiple organ dysfunction syndrome, and sepsis.

The urologic manifestations range from microscopic hematuria to severe hemorrhage with obstructive renal failure. Four grades have been identified: grade 1 (microscopic hematuria), grade 2 (macroscopic hematuria), grade 3 (hematuria with clots), and grade 4 (macroscopic hematuria with clots and